



Science

**SUPPLEMENTATION OF SPIRULINA AND VITAMIN C
ATTENUATED THE NEPHROTOXICITY INDUCED BY CISPLATIN
ADMINISTRATION**



Charu Munjal¹, Shalmoli Bhattacharyya²

¹ Department of Biophysics, Panjab University, INDIA

² Additional Professor, Department of Biophysics, Post graduate institute of medical research (PGIMER), Chandigarh-160012, INDIA

ABSTRACT

Overexposure of the kidneys to cisplatin [Cisplatin (cis- diaminedichloroplatinum II) (CDDP)] and cisplatin complexes cause degradation of the renal cells, and eventually lead to renal failure. Agents like antioxidants, modulators of nitric oxide (NO) and anti-apoptotic molecules are reported to reduce nephrotoxicity. In the present study we tested the hypothesis that supplementation of antioxidant spirulina and vitamin c reduces cisplatin induced nephrotoxicity. The study was carried out on female Balb /C mice of the following five groups: control (i); cisplatin (ii); vitamin c (iii); spirulina (iv); and vitamin c + spirulina + cisplatin (v). Plasma urea and creatinine levels were estimated 3 and 6 days after the injection of cisplatin and uptake studies with 99m Technetium-ethylene dicysteine was performed to assess the renal clearance rate. Kidneys were isolated and processed for electron microscopy and light microscopy. The activity and concentration of antioxidant enzymes such as glutathione, catalase, superoxide dismutase and GST was also determined. Dual supplementation of spirulina and vitamin c significantly protected cisplatin-induced increased levels of serum urea, creatinine, improved renal clearance rate, the declined renal antioxidant enzymes and increased LPO levels. Hence, we conclude that supplementation of spirulina and vitamin c had a beneficial effect on cisplatin induced nephrotoxicity in mice.

Keywords:

Cisplatin; Nephrotoxicity; Spirulina.

Cite This Article: Charu Munjal, and Shalmoli Bhattacharyya, “SUPPLEMENTATION OF SPIRULINA AND VITAMIN C ATTENUATED THE NEPHROTOXICITY INDUCED BY CISPLATIN ADMINISTRATION” International Journal of Research – Granthaalayah, Vol. 4, No. 1 (2016): 93-107.

1. INTRODUCTION

Cisplatin [Cisplatin (cis- diaminedichloroplatinum II) (CDDP)] is a widely used, effective chemotherapeutic agent that binds to and alkylates DNA, and triggers transcription inhibition, cell cycle arrest and apoptosis (Jordan and Carmo-Fonseca, 2000). Although CDDP is a potential chemotherapeutic candidate due to its ability to treat a wide variety of cancers, its clinical use has been limited due to its various side effects such as nephrotoxicity. CDDP-associated nephrotoxicity further accompanies proximal tubular injury and decreased glomerular filtration, hence causing renal failure (Jones et al., 1985). CDDP impairs the antioxidant defense system of the body, which results in increased oxidative stress (Cetin et al., 2006). Antioxidant therapy plays a promising role in alleviating cytotoxic effects of CDDP. Dietary and endogenous antioxidants have been reported to prevent cellular damage by reacting with and eliminating oxidizing free radicals (Weisburger, 2002). In this context, Spirulina, planktonic blue-green algae, is gaining increasing attention due to its high antioxidant potential (Kulshreshtha et al., 2008). A recent clinical trial documented the beneficial effects of Spirulina in hepatitis C infection and the protection against hydroxyurea induced teratogenic insult in mice (Vazquez-Sanchez et al., 2009; Yakoot and Salem, 2012). However, absence of appropriate experimental designs does not allow validating Spirulina as a functional food. Extensive studies are further required to explore the potential therapeutic benefits of Spirulina. Recent finding of Martínez-Galero et al (2015) demonstrated that Spirulina could be a useful adjuvant agent within clinical practice for treatment of experimental poisonings from arsenic, cadmium, carbon tetrachloride, deltamethrin, fluoride, hexachlorocyclohexane, iron, lead, lindane, and mercury. Vitamin c is another antioxidant that augments the chemotherapeutic efficacy of CDDP (Reddy et al., 2001). Recently, combined antioxidant therapy has gained attention for alleviating cisplatin-associated toxicity. Interestingly, combinational antioxidant therapy of vitamin c along with curcumin was found to be effective in protecting against CDDP-induced chromosomal damage (Antunes et al., 2000). In addition, our studies have shown combine supplementation of Spirulina and vitamin c alleviated the risk of hepatotoxicity (Bhattacharyya and Mehta, 2012). However, the role of combine supplementation in CDDP induced nephrotoxicity has not explored. In the view of above findings, the current study aim is to elucidate the mechanism of CDDP-associated nephrotoxicity and the possible protective effects of the combinational therapy of spirulina and vitamin c.

2. MATERIAL AND METHODS

Chemicals: CDDP was obtained from Dabur pharmaceuticals private ltd. *Spirulina* was procured from hydroline Biotech PVT Ltd, India as a kind gift. Vitamin c was obtained from Sigma Chemicals. Tc 99m was procured from BARC, Trombay, India.

Animals: Healthy female mice of Balb /C strain weighing 18-22gm were maintained on laboratory pelleted feed procured from Hindustan Lever Limited. The use of animals was approved by the Institute Ethics committee. The animals were divided into the following groups, with 8-10 animals in each group. Control animals (Gp I) were given normal saline (i.p injection), a single injection of CDDP (i.p 15mg/kg) was given to the animals in Gp II, *spirulina* (1000mg/kg) + vitamin c (500mg/kg) were supplemented together, orally for 5 days, followed by CDDP injection (gp iii), vitamin c (500mg/kg) was supplemented orally for 5 days followed by CDDP injection (gp iv) and *spirulina* (1000mg/kg body wt) was supplemented orally for 5 days followed by CDDP injection (gp v). Oral doses of *spirulina* and vitamin c were continued for

five days following CDDP treatment and then all the animals were sacrificed by cervical dislocation on the 6th day of the treatment (Premkumar et al., 2004). Kidneys were than isolated and processed for histological and biochemical assays.

Blood Collection: Blood samples were collected from the tail vein. Estimations of urea and creatinine were carried out using the plasma samples obtained from control and treated animals on the 3th and 6th days of the treatment.

Urea and Creatinine Estimation: Urea levels were quantified using diacetylmonoxime method previously described (Seaton and Ali, 1984). Results were expressed as mg of urea/dl (deciliter) of plasma. Creatinine levels were quantified by using the Randox kit marketed by *Recombigen Laboratories* and levels expressed as mg / dl of plasma. The animals were weighed before sacrificing. Kidneys were removed immediately and washed in ice cold normal saline (0.9% w/v NaCl).

Uptake studies with Technitium 99m labeled Ethylene di cysteine (^{99m}Tc-EC): Technetium 99m labeled Ethylene di cysteine, 50 μ Ci was injected intravenously (i.v) to mice for bio distribution studies. Mice were dissected after 5min, 10min, 20 min and 30min of i.v injection. The uptake of ^{99m}Tc EC was studied in the different groups at 10 min and 20 min post-isotope injection. **Light Microscopic examination:** For histological studies, kidneys from each of the control and treated animals were isolated and processed as previously described (Bhattacharyya and Mehta, 2012). The histological sections were then stained using hematoxylin-eosin (H&E) to analyze morphological changes.

Electron microscopic examination: A portion of kidney cortex was incised out and fixed in formaldehyde and glutaraldehyde made in 0.2M sodium cacodylate buffer (pH 7.2) for 10-12 hr at 4^oC. The specimens were then thoroughly washed in cacodylate buffer and post fixed in 1% osmium tetroxide (OsO₄). These were embedded in epon resin and ultrathin sections of various specimen blocks were cut using ultramicrotome. Followed by which sections were viewed under transmission electron microscope.

Preparation of Kidney Homogenate: The tissues were homogenized in 10 mM of ice cold phosphate buffer saline (PBS, pH7.4) using homogenizer for total disruption of tissue. The homogenized lysate was centrifuged at 10,000g for 30 minutes at 4^oC. The protein in lysate supernatant was quantified using Bradford assay and used for various biochemical estimations.

Reduced Glutathione (GSH): Estimation of GSH was performed in tissue homogenate by the method described previously (Moron et al., 1979). Briefly, 200 μ l of tissue homogenate was mixed with 40 μ l of 25% trichloroacetic acid (TCA), and kept at 4^oC. Precipitated proteins were separated by centrifugation (2000g, 15 minutes) and supernatant was diluted with 0.2M of potassium phosphate buffer (pH 8.0). Then, freshly prepared 0.6mM 5, 5-ditiobis 2-nitrobenzoic acid (DTNB) was added. A yellow colored complex was formed by reaction between GSH and DTNB (Ellmen's reaction). The optical density of this complex was measured at 412nm on a UV-Visible recording spectrophotometer (Shimadzu UV-160A).

Glutathione-S-Transferase (GST) activity assay: GST activity was determined spectrophotometrically as described previously (Habig et al., 1974) using 1-chloro-2, 4 dinitrobenzene (CDNB) as the substrate.

Superoxide Dismutase (SOD) activity assay: SOD activity was measured by the method described previously (Kono, 1978). The overall principle of the assay is the rate of nitrobluetetrazolium (NBT) dye reduction by superoxide anion radical in the presence of the enzyme, SOD.

Catalase (CAT): CAT activity was estimated by the U.V. spectrophotometer method using H₂O₂ as a substrate (Luck, 1957). The assay mixture was comprised of 150mM phosphate buffer (pH 7.0) containing H₂O₂ (30% v/v). The change in absorbance was read at 240nm for 2min at 30 sec intervals after addition of lysate in the assay mixture. The specific activity was calculated using a molar absorbance index for H₂O₂, expressed as nmole mg protein⁻¹min⁻¹.

Nitrite levels: measured using Greiss reagent (Raddassi et al., 1994). This assay is based on the enzymatic conversion of nitrate to nitrite by nitrate reductase. The reaction is followed by a colorimetric detection of nitrite at 540 nm as an azo dye product of the Griess reaction.

Citrulline: levels were measured by the method described previously (Boyde and Rahmatullah, 1980).

Lipid Peroxidation Assay (LPO): LPO was done using TCA (10% w/v) reagent which was added to the tissue homogenate in 0.1M Tris-HCl (pH 7.4). The reaction mixture was centrifuged (8000g, 10min) and 0.67% thiobarbituric acid (TBA) was added and kept at 100°C for 10min.

Samples were cooled and absorbance was taken at 532nm. The results were expressed as nanomoles of MDA-TBA chromophore formed/mg protein/30 min (Trush et al., 1981).

Statistical analyses: The data was analyzed by standard statistical methods (mean, SD, analysis of variance and unpaired student's t-tests wherever applicable). In comparing groups, 'p'≤0.05 was taken as significant.

3. RESULTS

Administration of CDDP to mice caused a significant increase in plasma urea 6th day (p≤0.001) when compared with the normal control group. There was also a significant increase (p≤0.001) in the plasma creatinine levels on the 6th day of CDDP injection. However, when CDDP treated groups were supplemented with *spirulina* and vitamin c resulted in significant reduction in creatinine levels when compared to the CDDP treated alone. The circulatory plasma urea was found to be significantly elevated on the 6th day of CDDP treatment and supplementation of *Spirulina* and vitamin c was effective in reducing the increased urea levels (p≤0.001) (**Fig. 1**). The kidneys showed maximum uptake of ^{99m}Tc-EC and peak activity by 10 min. of tracer injection (**Fig. 2**). The activity was observed to decline by 20 min post-injection in normal control animals. In the CDDP treated group, the ^{99m}Tc-EC was not flushed out of the kidneys

even after 20 min. post-injection. However, it was successfully cleared by the kidneys of control- and *Spirulina*-treated animals (**Fig 3**).

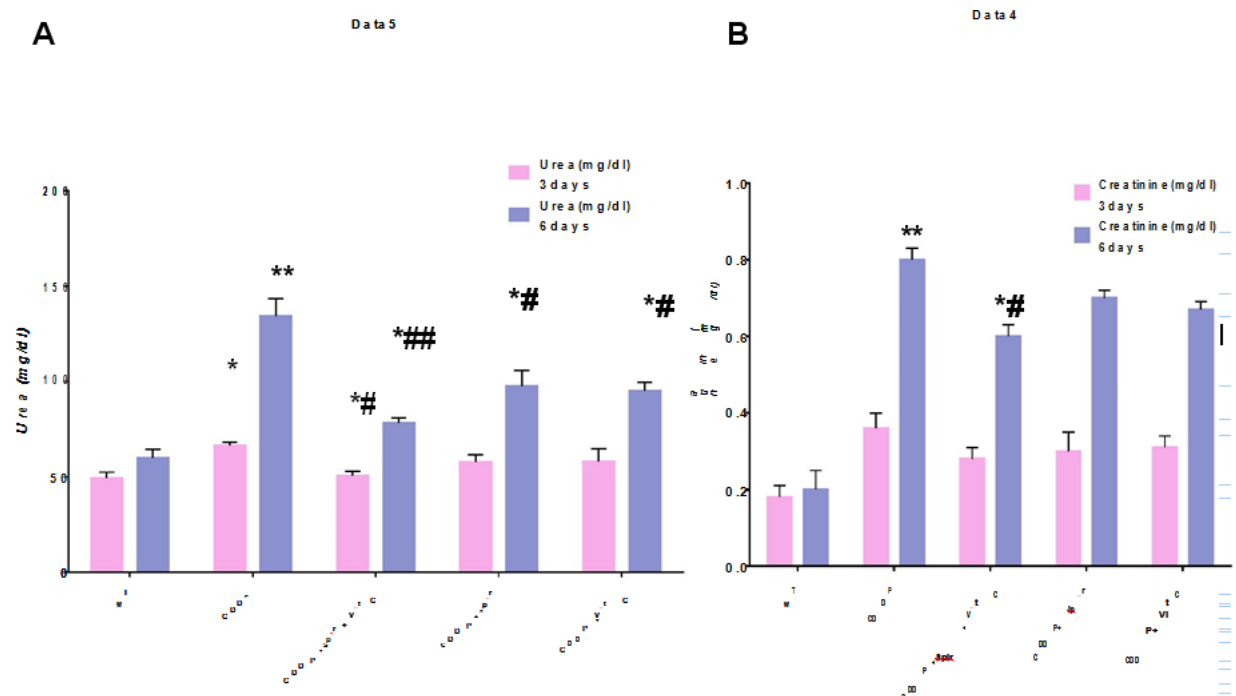


Figure 1: Histogram shows plasma levels of urea (A) and creatinine (B) measured at day 3 and day 6. Values are, Mean \pm S.D. (Standard Deviation) of 6-8 determinations. * $P \leq 0.05$, ** $P \leq 0.01$, *** $P \leq 0.001$: when the groups were compared with WT group; # $P \leq 0.05$, ## $P \leq 0.01$, ### $P \leq 0.001$: When the groups were compared with CDDP group.

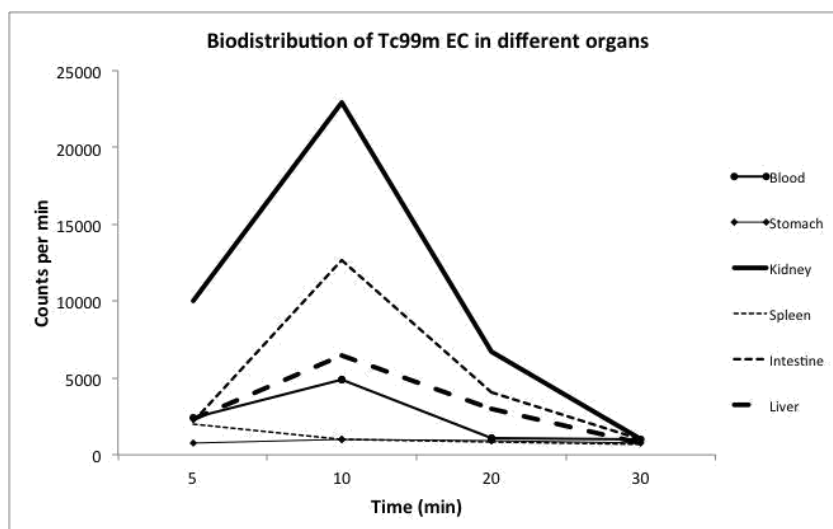


Figure 2: Biodistribution of Tc99m Ehylene dicysteine. The figure shows the distribution of Tc99m ethylene dicysteine at different time intervals following injection in mice. Most of the organs including kidney showed maximum activity after 10 minutes of intravenous injection. Other organs i.e. brain, heart, lungs, showed negligible activity at the selected time points.

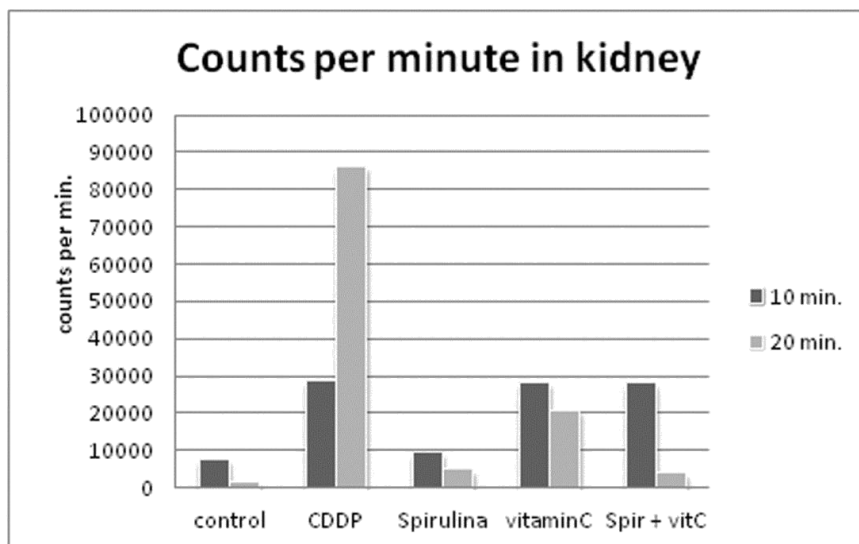


Figure 3: Histogram showing the excretion of Tc99m Ehylene dicysteine as indicated by the counts (y axis) in kidney at 10 min and 20 min post injection in 5 groups.

Morphometric studies of the kidney from various treatment groups are presented in **Fig.4**. In the present study, kidney sections from the CDDP treated mice had normal glomeruli but had marked tubular dilation (**Fig 4B**). Zones of necrosis were also observed—cells had been sloughed from the basement membrane in some tubules and necrotic debris had accumulated in the lumen. In a few regions, karyohexis (apoptosis) was noted. Administration of both *Spirulina* & vitamin c together resulted in an almost normal pathology of the kidney tissue under the light microscope (**Fig 4C**). The renal parenchyma showed almost normal structural organization along with few foci showing flattening and dilation of the tubules. Relatively less flattening was observed in kidney sections of groups supplemented with vitamin c alone (**Fig 4D**) or *spirulina* alone (**Fig 4E**). Focal regions that necrosis were substantially reduced in dual supplementation group compared to the CDDP treated mice.

Ultramicroscopic analysis of kidneys from various treatment groups are represented in **Fig 5**. Degenerative changes were found in the glomerular cells of CDDP treated animals. The cellular integrity of the podocytes was compromised, and in places, the cytoplasmic foot processes had disappeared as shown **Fig 5B**. The basement membrane was thinner and disintegrated at places. Vacuolization was observed in the cytoplasm in CDDP treated group. Podocytes observed in the visceral epithelium of the glomerulus showed normal projection in electromicrographic sections of control mice **Fig 5A**, but were disrupted in the kidneys following CDDP administration **Fig 5B**. In-addition, cellular morphology was almost intact in CDDP treated mice when supplemented with *spirulina* and vitamin c, as observed in electron-micrographs **Fig 5C**. Also, podocyte foot processes were normal in structure as compared to the CDDP treated group. Loss of brush border was also observed in renal electromicrographic sections from CDDP treated mice. There was an almost intact brush border in electromicrographic sections of CDDP treated mice supplemented with *spirulina* and vitamin c.

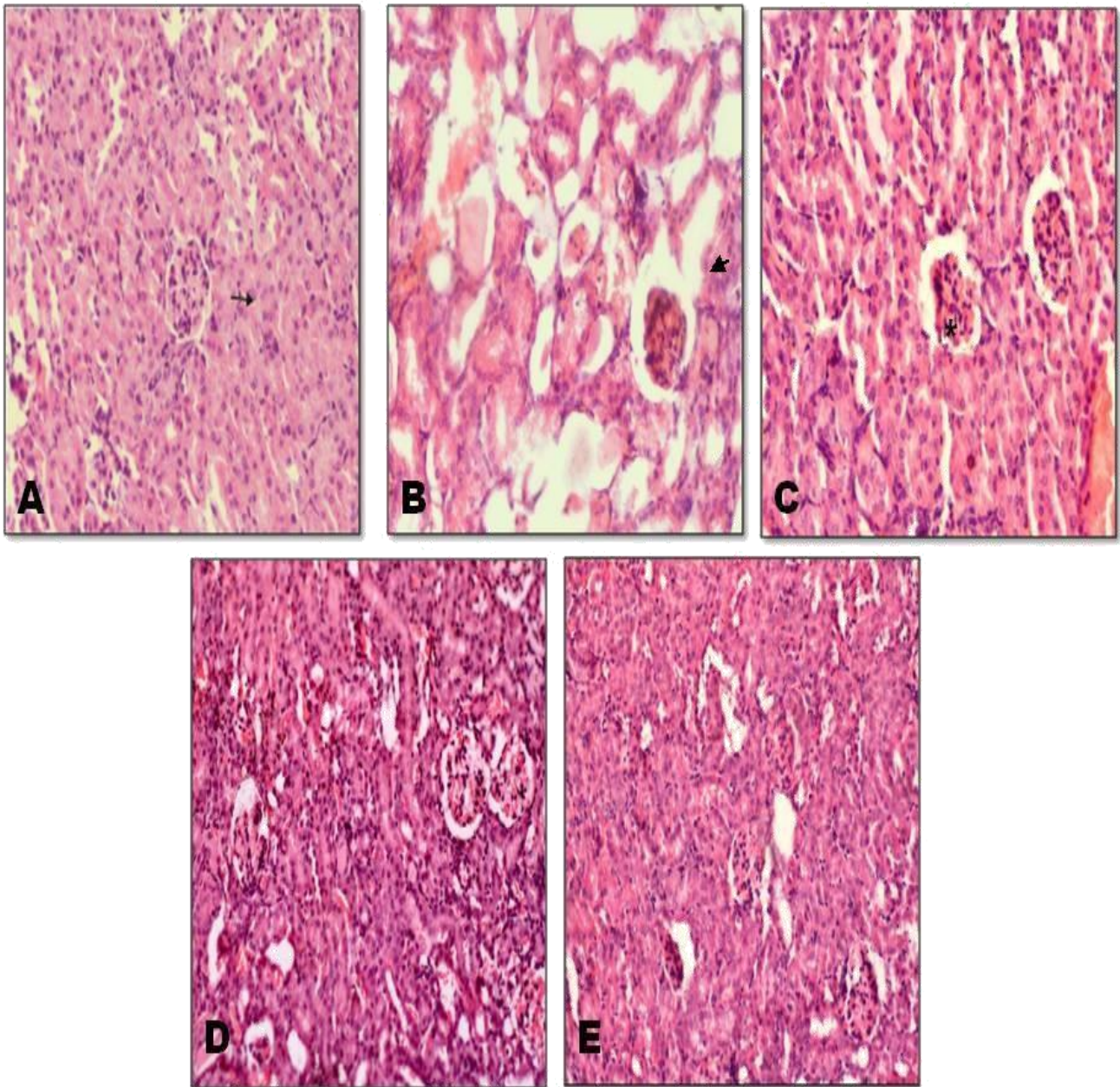


Figure 4: Morphological assessment of renal histological section using hematoxylin and eosin staining. Photomicrographs shows renal sections from control WT mice showing normal intact morphology of glomeruli & tubules (A) when compared to kidneys from CDDP treated mice that showed altered glomerular morphology necrotic changes, dialation and flattening of tubules; (arrows, B). This altered renal morphology was somewhat restored with mild focal disruption when CDDP treated group were supplemented with spirulina and vitamin C (C). Renal sections from cisplatin treated mice supplemented with vitamin c showing focal dialation& flattening of tubules, pale eosin cast in luminal region (D). Kidney sections from cisplatin treated mice supplemented with spirulina showing almost normal morphology with mild dilation of tubules (E).

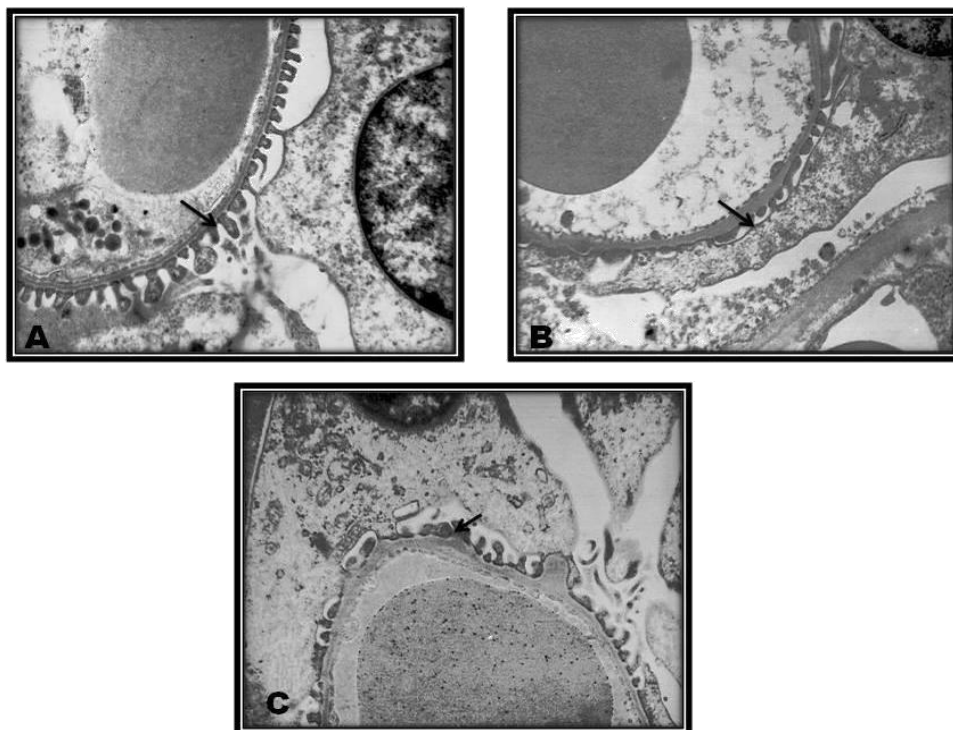


Figure 5: Ultra-microscopic analysis in renal tissue sections. Electron-micrograph of renal tissue from control WT mice showing normal podocytes projection and intact basement membrane(A). Electron-micrograph of renal tissue in cisplatin treated mice showing rupturing and flattening of podocyte as indicated by the arrows (B). Electron-micrograph of renal tissue in cisplatin treated mice supplemented with spirulina+ vitamin c showing almost intact podocytes with focal rupturing (C).

BIOCHEMICAL STUDIES

SOD and CAT activities were found to be inhibited significantly in the kidneys ($p \leq 0.01$) in CDDP treated mice compared to control (Table 1). And *spirulina* and vitamin c supplementation, restored the SOD and CAT activities to the normal levels. Similar observations were observed in the groups where only *spirulina* or only vitamin c were supplemented to the CDDP treated group as shown in Table 1. GST activity that has been a potential target for various therapeutic drugs, our results showed significant decline ($p \leq 0.001$) in GST activity in the kidneys was observed following CDDP treatment ($\mu\text{mol/mg}$) as shown in Table 1. The supplementation of *spirulina* or vitamin c alone or both *spirulina* and vitamin c together significantly raised the GST levels compared to the control ($p \leq 0.01$).

The current results show that the administration of CDDP to mice resulted in significantly decline in renal GSH levels. Administration of *spirulina* or vitamin c alone to CDDP treated mice showed some increase in GSH levels while combined supplementation of *Spirulina* and vitamin c to these mice showed additive effect on GSH levels.

In the present study, MDA production ($\mu\text{mol mg}^{-1}$) was used as a marker of lipid peroxidation in different groups studied. There was a significant increase in lipid peroxidation in kidneys of the

CDDP treated animals which was inhibited following combined supplementation with *spirulina* and vitamin c. Supplementation with *spirulina* alone or vitamin c alone to the CDDP treated groups also showed an inhibition in MDA when compared to the group where only CDDP was **Table 1.**

Table 1: Levels of antioxidant enzymes (SOD, catalase, GST, GSH), lipid peroxidation, nitrite and citrulline in different treatment

Group names	SOD ($\mu\text{g}/\text{mg}$)	Catalase (mmol/mg)	GST ($\mu\text{mol}/\text{mg}$)	GSH ($\mu\text{mol}/\text{mg}$)	LPO ($\mu\text{mol}/\text{mg}$)	Nitrite (mmol/mg)	Citrulline ($\mu\text{mol}/\text{mg}$)
Control	4.19 \pm 0.7	0.39 \pm 0.03	0.52 \pm 0.09	1.36 \pm 0.3	0.15 \pm 0.04	3.98 \pm 0.62	145.1 \pm 7.1
CDDP	2.81 \pm 0.3**	0.29 \pm 0.012**	0.27 \pm 0.07***	0.91 \pm 0.1**	0.50 \pm .08***	6.94 \pm 1.19**	185.9 \pm 13.3***
<i>Spirulina</i> + Vitamin C + CDDP	3.73 \pm 1.1	0.33 \pm 0.02 [#]	0.34 \pm 0.084 ^{##}	1.14 \pm 0.2	0.30 \pm .03 ^{###}	6.10 \pm 0.06 ^{##}	135.3 \pm 11.8
<i>Spirulina</i> + CDDP	3.45 \pm 0.5 ^{##}	0.31 \pm 0.01 [#]	0.32 \pm 0.05 ^{##}	1.09 \pm 0.1 [#]	0.32 \pm .02 ^{###}	6.19 \pm 0.79 ^{##}	174.6 \pm 28.3 [#]
Vitamin C + CDDP	3.97 \pm 0.6	0.31 \pm 0.01 [#]	0.27 \pm 0.09 ^{##}	0.99 \pm 0.1**	0.40 \pm 0.01**	6.39 \pm 0.39 ^{##}	171.1 \pm 13.2 [#]

Values are, Mean \pm S.D. (Standard Deviation) of 6-8 determinations

*P \leq 0.05, **P \leq 0.01, ***P \leq 0.001: When the groups were compared with control group

[#]P \leq 0.05, ^{##}P \leq 0.01, ^{###}P \leq 0.001: When the groups were compared with CDDP group

Levels of antioxidant enzymes (SOD, catalase, GST, GSH), lipid peroxidation and reactive nitrogen species (nitrate and citrulline) in different treatment groups. Values are, Mean \pm S.D. (Standard Deviation) of 6-8 determinations. *P \leq 0.05, **P \leq 0.01, ***P \leq 0.001: when the groups were compared with WT group; [#]P \leq 0.05, ^{##}P \leq 0.01, ^{###}P \leq 0.001: When the groups were compared with CDDP group

NO and citrulline levels were significantly up-regulated in kidneys of the mice treated with CDDP alone (**Table 1**). However, combined supplementation of *spirulina* and vitamin c resulted in a significant reduction of the NO and citrulline levels in the kidneys of CDDP treated animals.

4. DISCUSSION

The present study evaluated the protective effect of combined treatment of food supplement *spirulina* and antioxidant vitamin c on CDDP associated renal toxicity. The plasma serum creatinine and urea levels are usually routinely used biomarkers for the assessment of renal function. In the present study, plasma urea and creatinine levels were estimated in all groups on the 4th and 6th days in order to assess the renal toxicity. The results demonstrated a significant increase in levels of plasma urea and creatinine in CDDP-treated mice (15mg/kg body wt.), which clearly indicated intrinsic renal failure. In-addition, we found that when vitamin c alone was supplemented prior to CDDP administration, there was a sharp decline in plasma creatinine and urea compared to the levels exhibited when CDDP alone was given to the mice. This observation is in accordance with the previous reports in which vitamin c significantly prevented the increase of CDDP-induced serum creatinine and urea concentrations (Ajith et al., 2007). Furthermore, reports showed that antioxidant supplementation of grape extract alleviate CDDP-induced renal toxicity by reducing the plasma urea and creatinine levels (Yousef et al., 2009). Previous reports have shown that *spirulina* effectively attenuated the cyclosporine-induced nephrotoxicity in rats (Khan et al., 2006). The rationale for the dual supplementation of *spirulina* and vitamin c was to establish the nephroprotective potential of combined therapy, as individually they have been shown to have antioxidant potential. Vitamin c has also been reported to enhance the efficacy of intestinal absorption of *spirulina* (Ray et al., 2007). Increased plasma urea levels in CDDP treated group

indicates acute tubular degeneration minimal inflammation which further leads to tubular damage. This further causes a decrease in glomerular filtration rate. Acute renal failure due to ischemia and nephrotoxic drugs, resulting in varying degrees of morphological damage, especially in the S3 segment of the proximal tubules (Dizdar et al., 2011). CDDP induced reduced glomerular filtration rates (GFR) could possibly be caused by afferent vasoconstriction and an altered ultrafiltration coefficient (Camano et al., 2010). ^{99m}Tc-Ethylenedicycysteine (^{99m}Tc-EC) is a radiopharmaceutical that has been routinely used in to study renal dynamics and renal clearance (Kabasakal et al., 1995). ^{99m}Tc-EC helps in evaluating renal functions and its elimination usually occurs through active tubular transport (Moran, 1999). The glomerular tubules are affected by CDDP and normal kidney function is impaired. As a result, there is retention of EC for a longer time in CDDP-treated animals. The early clearance of EC with *spirulina* supplementation in the CDDP-treated animals indicates the beneficial effects of *spirulina* on kidney function. The renal histoarchitecture of the CDDP treated mice showed significant changes as compared to the normal control. There was no evidence of tubular necrosis in the *Spirulina* and vitamin c supplemented group. Here the proximal tubules were intact, lined by normal epithelium suggestive of normal morphology with combine treatment. In-addition, marked pathological changes in the kidneys due to damage caused by CDDP was prevented significantly in mice supplemented with Vitamin c and *Spirulina* where almost intact cytoplasmic and brush border morphology was seen, thus indicating its ameliorating potential. Oil red O dye also showed significant accumulation of intracellular lipids in the CDDP treated group compared to the control mice (data not shown). This was predominantly observed in regions corresponding to the proximal tubules, which suggested that reduced triglycerides (TG) catabolism, in addition to increased accumulation of free fatty acids, may be the important mechanism of TG accumulation in proximal tubules. However, supplementation of *spirulina* and vitamin c significantly attenuated the accumulation of neutral lipids induced by CDDP. Furthermore, there was a direct correlation between higher plasma urea levels and tubular degenerate. This was also accompanied by podocytes rupturing following the CDDP treatment was an interesting finding in the electron microscopic studies. Previous studies demonstrated that podocyte injury leads to proteinuria. In addition, selective damage of the podocyte *in vivo* leads to albuminuria and the deletion of several molecules of the podocyte, while damage of the slit diaphragm results in severe proteinuria (Laurens et al., 1995). The foot processes of the podocytes are invariably exposed to the hydrodynamic filtration pressure, which substantiates the need for reinforcement of tight junctional complexes to anchor them to the cytoskeleton. Podocyte injury eventually results in end stage renal stage renal failure mediated by elevated oxidative stress. In our histological findings, we found podocyte injury in the CDDP-treated group, which were alleviated by co-supplementation of vitamin c and *spirulina*. Previous findings have shown that CDDP toxicity in proximal tubular cells was morphologically characterized by tubular necrosis as a result of oxidative stress (Kanwar and Rosenzweig, 1982). Although the exact mechanism of CDDP-induced nephrotoxicity is not well understood, evidence pointed out that CDDP-induced nephrotoxicity occurred partially via oxidative stress and crosslinking of cellular thiols and membrane lipid peroxidation. Accumulating evidences suggests, CDDP treatment generates active oxygen species, such as superoxide anion and hydroxyl radical that stimulate lipid peroxidation in the renal tissue (Meyer and Madias, 1994; Ajith et al., 2007; Jung et al., 2014). Consistently, we observed increased lipid peroxidation, stimulation of oxidant generation and marked deterioration of endogenous antioxidant as evident from the decrease in catalase and SOD activity in the kidneys 6 days after CDDP administration. It is a well-documented fact that CDDP causes lipid peroxidation via ROS generation and it was observed that antioxidant preconditioning could reverse the CDDP-induced lipid peroxidation (Dilliogluligil et al., 2005). CDDP treatment caused an increase in expression of inducible NO synthase (iNOS) in renal mitochondria, which resulted in an elevation of NO release and increased generation of reactive nitrogen species; hence, decreased cellular viability. In addition, the cytotoxic effects of NO depend on the redox state of the cell and its ability

to generate peroxynitrite (ONOO) anions. Peroxynitrite, a highly reactive nitrogen species formed during the interaction of NO and O₂, could attack a wide variety of biological targets (Jung et al., 2009). The present study indicated significant elevation in NO levels in the renal tissue of CDDP-treated mice. Also, we observed that vitamin c and *spirulina* supplementation attenuated the elevated levels of NO due to CDDP-induced toxicity. There was reduction in SOD activities suggestive indicator of impaired lipid-phase antioxidant defense system due to CDDP treatment. CDDP causes lipid peroxidation via ROS generation has been established based on previous reports. Several reports showed that antioxidant preconditioning could reverse the CDDP-induced lipid peroxidation (Antunes et al., 2000; Yousef et al., 2009; Kuriakose and Kurup, 2011). In our study, vitamin c and *spirulina* supplementation attenuated the lipid peroxidation in CDDP treated mice providing convincing evidence for the involvement of ROS in CDDP-induced lipid peroxidation. Consistently, previous studies have suggested protective role of *spirulina* against the damage induced by lipid peroxidation in liver and kidney (Ponce-Canchihuaman et al., 2010). *Spirulina* was found to be a safe supplement in a randomized clinical trial on an elderly population to treat immunosenescence (Selmi et al., 2011). It has been found to be neuroprotective in Parkinsonian model of rats (Chattopadhyaya et al., 2015) and the neuroregenerative role of *Spirulina* has been reported to be mediated by the dynamic regulation of multiple biological processes (Pentón-Rol, 2015).

Overall, this study emphasizes the improvement of CDDP-induced nephrotoxicity through *spirulina* and vitamin c may be possible due to their potential antioxidant properties. These agents probably improved renal function via attenuating the oxidation-stress-mediated decline in glomerular filtration rate and renal haemodynamics. The antioxidant effect of *Spirulina* against lead acetate induced hepatotoxicity and nephrotoxicity has been studied and it is suggested that *spirulina displays* protective effects against lead acetate induced lipid peroxidation of lipids (Ponce-Canchihuaman et al., 2010). In another study, Gad et al also demonstrated free- radical scavenging properties and antioxidant potential of *spirulina* (Gad et al., 2011). Vitamin c is a potent, free-radical scavenger and prevents oxidative damage by utilizing free radicals. The protective effect of ascorbic acid against oxidative damage induced by inorganic arsenic in liver and rat kidneys has been reported (Sohini and Rana, 2007).

5. CONCLUSION AND RECOMMENDATION

Hence from the present study, we conclude that CDDP administration is nephrotoxic to mice, whereas *spirulina* and vitamin c co-supplementation protect the kidneys from CDDP-induced toxicity as summarized in Fig 6. This suggests the risk of nephrotoxicity could be attenuated by combined supplementation of *Spirulina* and Vitamin c before and during the CDDP treatment, thus emphasizing the role of nutrition management in cancer chemotherapy. This study provides an experimental evidence for possible beneficial effects of *Spirulina* supplementation during chemotherapy regimen.

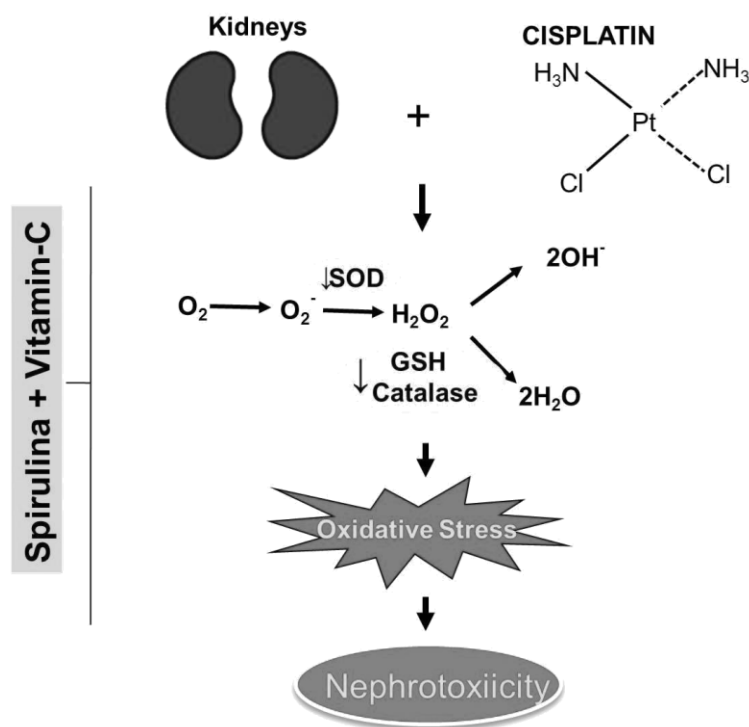


Figure 6: The protective activity of Spirulina and Vitamin c combination during cisplatin nephrotoxicity. This figure summarizes the result of our study which shows the generation of oxidative stress in kidney due to cisplatin treatment that was ameliorated by administration of spirulina and vitamin c.

6. ACKNOWLEDGMENTS

The authors thank Dr. Utpal Sen for technical advice and Courtney Kuessal for helping with the editing.

7. REFERENCES

- [1] Ajith, T. A., Usha, S. and Nivitha, V. (2007). Ascorbic acid and alpha-tocopherol protect anticancer drug cisplatin induced nephrotoxicity in mice: a comparative study. *Clinica chimica acta; international journal of clinical chemistry* 375, 82-86.
- [2] Antunes, L. M., Araujo, M. C., Darin, J. D. and Bianchi, M. L. (2000). Effects of the antioxidants curcumin and vitamin C on cisplatin-induced clastogenesis in Wistar rat bone marrow cells. *Mutat Res* 465, 131-137.
- [3] Bhattacharyya, S. and Mehta, P. (2012). The hepatoprotective potential of Spirulina and vitamin C supplementation in cisplatin toxicity. *Food & function* 3, 164-169.
- [4] Boyde, T. R. and Rahmatullah, M. (1980). Optimization of conditions for the colorimetric determination of citrulline, using diacetyl monoxime. *Anal Biochem* 107, 424-431.
- [5] Camano, S., Lazaro, A., Moreno-Gordaliza, E., Torres, A. M., de Lucas, C., Humanes, B., Lazaro, J. A., Milagros Gomez-Gomez, M., Bosca, L. and Tejedor, A. (2010). Cilastatin attenuates cisplatin-induced proximal tubular cell damage. *The Journal of pharmacology and experimental therapeutics* 334, 419-429.

- [6] Cetin, R., Devrim, E., Kilicoglu, B., Avci, A., Candir, O. and Durak, I. (2006). Cisplatin impairs antioxidant system and causes oxidation in rat kidney tissues: possible protective roles of natural antioxidant foods. *J Appl Toxicol* 26, 42-46.
- [7] Chattopadhyaya I, Gupta S, Mohammed A, Mushtaq N, Chauhan S, Ghosh S. (2015). Neuroprotective effect of *Spirulina fusiform* and amantadine in the 6-OHDA induced Parkinsonism in rats. *BMC Complement Altern Med* 15,296.
- [8] Dillioglugil, M. O., Maral Kir, H., Gulkac, M. D., Ozon Kanli, A., Ozdogan, H. K., Acar, O. and Dillioglugil, O. (2005). Protective effects of increasing vitamin E and a doses on cisplatin-induced oxidative damage to kidney tissue in rats. *Urologia internationalis* 75, 340-344.
- [9] Dizdar, O., Demirci, U. and Ozcan, M. F. (2011). "Unfit" for Cisplatin: on basis of which GFR? *Journal of clinical oncology : official journal of the American Society of Clinical Oncology* 29, 3945.
- [10] Gad, A. S., Khadrawy, Y. A., El-Nekeety, A. A., Mohamed, S. R., Hassan, N. S. and Abdel-Wahhab, M. A. (2011). Antioxidant activity and hepatoprotective effects of whey protein and *Spirulina* in rats. *Nutrition* 27, 582-589.
- [11] Habig, W. H., Pabst, M. J. and Jakoby, W. B. (1974). Glutathione S-transferases. The first enzymatic step in mercapturic acid formation. *J Biol Chem* 249, 7130-7139.
- [12] Jones, T. W., Chopra, S., Kaufman, J. S., Flamenbaum, W. and Trump, B. F. (1985). Cis-diamminedichloroplatinum (II)-induced acute renal failure in the rat. Correlation of structural and functional alterations. *Lab Invest* 52, 363-374.
- [13] Jordan, P. and Carmo-Fonseca, M. (2000). Molecular mechanisms involved in cisplatin cytotoxicity. *Cell Mol Life Sci* 57, 1229-1235.
- [14] Jung, M., Hotter, G., Vinas, J. L. and Sola, A. (2009). Cisplatin upregulates mitochondrial nitric oxide synthase and peroxynitrite formation to promote renal injury. *Toxicology and applied pharmacology* 234, 236-246.
- [15] Jung, S. H., Kim, H. J., Oh, G. S., Shen, A., Lee, S., Choe, S. K., Park, R. and So, H. S. (2014). Capsaicin Ameliorates Cisplatin-Induced Renal Injury through Induction of Heme Oxygenase-1. *Molecules and cells* 37, 234-240.
- [16] Kabasakal, L., Atay, S., Vural, V. A., Ozker, K., Sonmezoglu, K., Demir, M., Uslu, I., Isitman, A. T. and Onsel, C. (1995). Evaluation of technetium-99m-ethylenedicysteine in renal disorders and determination of extraction ratio. *Journal of nuclear medicine : official publication, Society of Nuclear Medicine* 36, 1398-1403.
- [17] Kanwar, Y. S. and Rosenzweig, L. J. (1982). Altered glomerular permeability as a result of focal detachment of the visceral epithelium. *Kidney international* 21, 565-574.
- [18] Khan, M., Shobha, J. C., Mohan, I. K., Rao Naidu, M. U., Prayag, A. and Kutala, V. K. (2006). *Spirulina* attenuates cyclosporine-induced nephrotoxicity in rats. *J Appl Toxicol* 26, 444-451.
- [19] Kono, Y. (1978). Generation of superoxide radical during autoxidation of hydroxylamine and an assay for superoxide dismutase. *Arch Biochem Biophys* 186, 189-195.
- [20] Kulshreshtha, A., Zacharia, A. J., Jarouliya, U., Bhadauriya, P., Prasad, G. B. and Bisen, P. S. (2008). *Spirulina* in health care management. *Curr Pharm Biotechnol* 9, 400-405.
- [21] Kuriakose, G. C. and Kurup, M. G. (2011). Antioxidant and antihepatotoxic effect of *Spirulina laxissima* against carbon tetrachloride induced hepatotoxicity in rats. *Food & function* 2, 190-196.

- [22] Laurens, W., Battaglia, C., Foglieni, C., De Vos, R., Malanchini, B., Van Damme, B., Vanrenterghem, Y., Remuzzi, G. and Remuzzi, A. (1995). Direct podocyte damage in the single nephron leads to albuminuria in vivo. *Kidney international* 47, 1078-1086.
- [23] Luck, H. (1957). [Inactivation of catalase by hydrogen peroxide. I. Studies on the maximum amount of hydrogen peroxide cleavable by the enzyme]. *Biochemische Zeitschrift* 329, 165-174.
- [24] Martínez-Galero E, Pérez-Pastén R, Perez-Juarez A, Fabila-Castillo L, Gutiérrez-Salmeán G, Chamorro G (2015). Preclinical antitoxic properties of *Spirulina* (*Arthrospira*). *Pharm Biol.* 2015 Oct 6:1-9. [Epub ahead of print]
- [25] Meyer, K. B. and Madias, N. E. (1994). Cisplatin nephrotoxicity. *Mineral and electrolyte metabolism* 20, 201-213.
- [26] Moran, J. K. (1999). Technetium-99m-EC and other potential new agents in renal nuclear medicine. *Seminars in nuclear medicine* 29, 91-101.
- [27] Moron, M. S., Depierre, J. W. and Mannervik, B. (1979). Levels of glutathione, glutathione reductase and glutathione S-transferase activities in rat lung and liver. *Biochim Biophys Acta* 582, 67-78.
- [28] Pentón-Rol G, Lagumersindez-Denis N, Muzio L, Bergami A, Furlan R, Fernández-Massó JR, Nazabal-Galvez M, Llópez-Arzuaga A, Herrera-Rolo T, Veliz-Rodriguez T, Polentarutti N, Marín-Prida J, Raíces-Cruz I, Valenzuela-Silva C, Teixeira MM, Pentón-Arias E (2015). Comparative Neuroregenerative Effects of C-Phycocyanin and IFN-Beta in a Model of Multiple Sclerosis in Mice. *J Neuroimmune Pharmacol.* Nov 10. [Epub ahead of print]
- [29] Ponce-Canchihuaman, J. C., Perez-Mendez, O., Hernandez-Munoz, R., Torres-Duran, P. V. and Juarez-Oropeza, M. A. (2010). Protective effects of *Spirulina maxima* on hyperlipidemia and oxidative-stress induced by lead acetate in the liver and kidney. *Lipids in health and disease* 9, 35.
- [30] Premkumar, K., Abraham, S. K., Santhiya, S. T. and Ramesh, A. (2004). Protective effect of *Spirulina fusiformis* on chemical-induced genotoxicity in mice. *Fitoterapia* 75, 24-31.
- [31] Raddassi, K., Berthon, B., Petit, J. F. and Lemaire, G. (1994). Role of calcium in the activation of mouse peritoneal macrophages: induction of NO synthase by calcium ionophores and thapsigargin. *Cellular immunology* 153, 443-455.
- [32] Ray, S., Roy, K. and Sengupta, C. (2007). In vitro evaluation of protective effects of ascorbic acid and water extract of *Spirulina plantesis* (blue green algae) on 5-fluorouracil-induced lipid peroxidation. *Acta poloniae pharmaceutica* 64, 335-344.
- [33] Reddy, V. G., Khanna, N. and Singh, N. (2001). Vitamin C augments chemotherapeutic response of cervical carcinoma HeLa cells by stabilizing P53. *Biochem Biophys Res Commun* 282, 409-415.
- [34] Seaton, B. and Ali, A. (1984). Simplified manual high performance clinical chemistry methods for developing countries. *Medical laboratory sciences* 41, 327-336.
- [35] Selmi, C., Leung, P. S., Fischer, L., German, B., Yang, C. Y., Kenny, T. P., Cysewski, G. R. and Gershwin, M. E. (2011). The effects of *Spirulina* on anemia and immune function in senior citizens. *Cellular & molecular immunology* 8, 248-254.
- [36] Sohini and Rana, S. V. (2007). Protective effect of ascorbic acid against oxidative stress induced by inorganic arsenic in liver and kidney of rat. *Indian journal of experimental biology* 45, 371-375.

- [37] Trush, M. A., Mimnaugh, E. G., Ginsburg, E. and Gram, T. E. (1981). *In vitro* stimulation by paraquat of reactive oxygen-mediated lipid peroxidation in rat lung microsomes. *Toxicology and applied pharmacology* 60, 279-286.
- [38] Vazquez-Sanchez, J., Ramon-Gallegos, E., Mojica-Villegas, A., Madrigal-Bujaidar, E., Perez-Pasten-Borja, R. and Chamorro-Cevallos, G. (2009). *Spirulina maxima* and its protein extract protect against hydroxyurea-teratogenic insult in mice. *Food Chem Toxicol* 47, 2785-2789.
- [39] Weisburger, J. H. (2002). Lycopene and tomato products in health promotion. *Exp Biol Med (Maywood)* 227, 924-927.
- [40] Yakoot, M. and Salem, A. (2012). *Spirulina platensis* versus silymarin in the treatment of chronic hepatitis C virus infection. A pilot randomized, comparative clinical trial. *BMC gastroenterology* 12, 32.
- [41] Yousef, M. I., Saad, A. A. and El-Shennawy, L. K. (2009). Protective effect of grape seed proanthocyanidin extract against oxidative stress induced by cisplatin in rats. *Food Chem Toxicol* 47, 1176-1183.